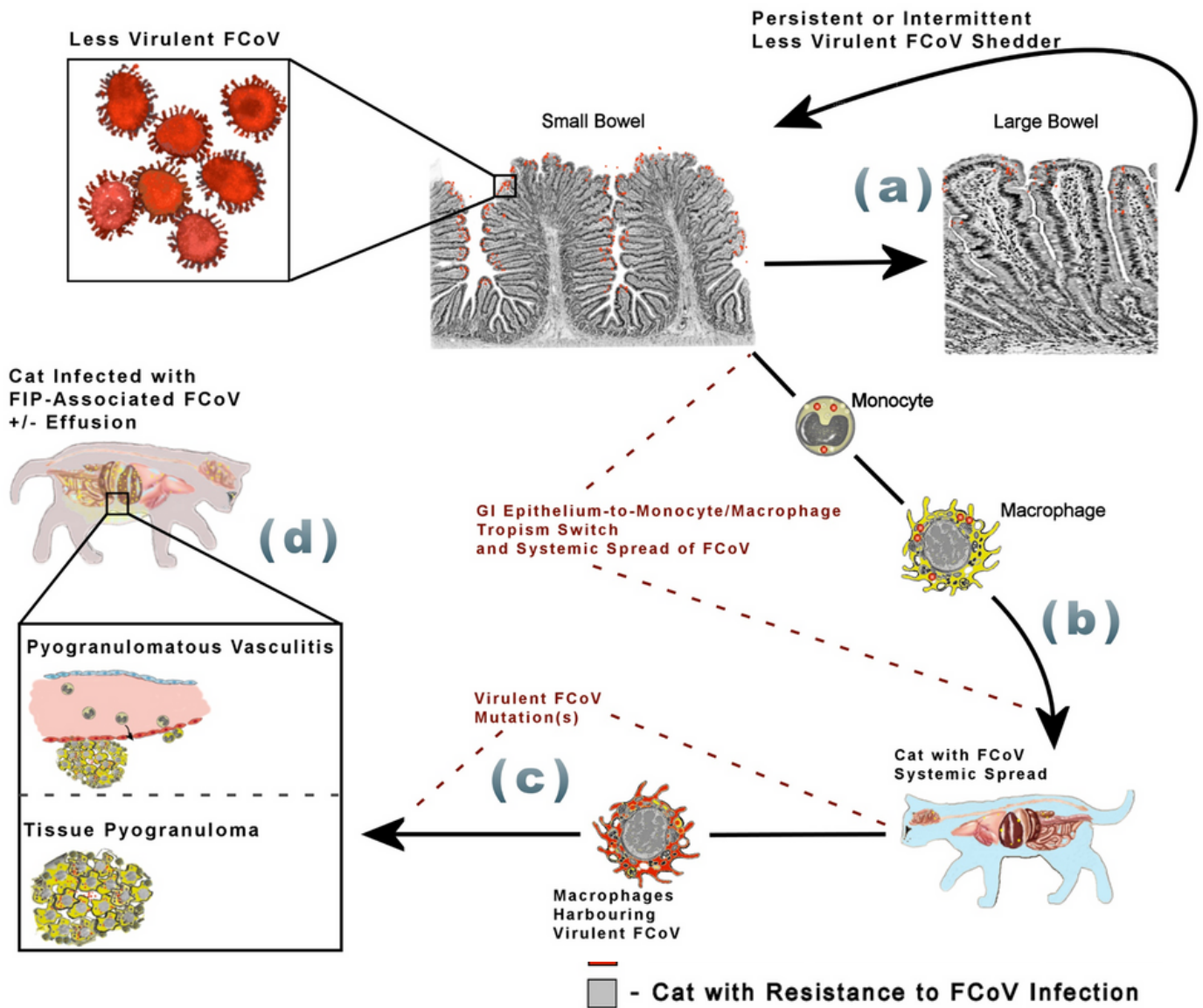


# AAFP/EveryCat Feline Infectious Peritonitis Diagnosis Guidelines

## Pathogenesis Pathway from Less-virulent FCoV Infection to FIP-associated FCoV



### SUPPLEMENTAL FIGURE 4: Pathogenesis Pathway from Less-virulent FCoV Infection to FIP-associated FCoV

Diagram showing the pathogenesis pathway followed from less-virulent FCoV infection to monocyte and macrophage tropism switch, which leads to systemic spread of FCoV and eventually development of FIP-associated FCoV. (a) Some infected cats become long-term persistent or intermittent shedders when colonic columnar epithelial cells harbor a persistent FCoV infection. (b) Tropism switch of FCoV from gastrointestinal epithelium to monocytes/macrophages allows systemic spread of the virus, but this tropism switch does not necessarily confer FIP-associated FCoV disease. (c) Additional viral mutation(s), yet unidentified, are required before FIP-associated FCoV arises. (d) FIP-associated FCoV can lead to pyogranulomatous vasculitis, which contributes to effusions, and/or tissue-associated pyogranulomas. Cats with FIP can present with both effusions and pyogranulomas together.

For more information, visit [catvets.com/fip](http://catvets.com/fip) & [everycat.org/aafp-fip-guidelines](http://everycat.org/aafp-fip-guidelines).